

Effectiveness and Safety of a Single 7-French Plastic Stent for Endoscopic Ultrasound-guided Pancreatic Pseudocyst Drainage and Long-term Follow-up Outcomes

Nonthalee Pausawasdi^{1*}, Manus Rugivarodom¹, Pongprueth Rujirachun¹, Phunchai Charatchareonwithaya¹, Tanyaporn Chantarojanasiri², Yongyut Sirivatanauksorn³

¹Department of Medicine, Siriraj GI Endoscopy Center, Division of Gastroenterology, Faculty of Medicine, Siriraj Hospital, Mahidol University, Bangkok, Thailand,

²Department of Internal Medicine, Division of Gastroenterology, Rajavithi Hospital, Bangkok, Thailand, ³Department of Surgery, Faculty of Medicine, Siriraj Hospital, Mahidol University, Bangkok, Thailand

Abstract

Background: Endoscopic ultrasound (EUS)-guided cystogastrostomy with a single 7-French (Fr) double-pigtail stent (DPS) is less popular due to the concern of stent patency. We aimed to assess the effectiveness, complications, and long-term outcomes of a single 7-Fr DPS in the endoscopic drainage of uncomplicated pseudocysts, containing no or minimal (<10%) debris. **Methods:** A retrospective review of patients with pancreatic pseudocysts, who underwent EUS-guided cystogastrostomy during 2010–2018, and a systematic review of the literature were conducted. **Results:** Of 45 patients, 14 patients underwent endoscopic drainage of uncomplicated pseudocysts using a single 7-Fr × 5 cm DPS. The mean cyst size was 10.2 ± 3.5 cm. Stent placement had a 100% technical and clinical success, defined as complete resolution of symptoms and regression of the cyst size by more than 50% at 8 weeks after drainage. The median follow-up was 42.4 months (range, 10–103). The pseudocysts resolved without recurrence in 92.8%. Spontaneous stent dislodgment was noted in 70% at a mean follow-up of 18 months. Additional interventions were required in 14% of cases due to stent occlusion and migration. A systematic review of literature related to EUS-guided cystogastrostomy using single and multiple plastic stents included 9 of 333 studies (222 patients). The analysis showed the pooled clinical success of 89% (95% confidence interval [CI], 82.0–94.2) and complication rate of 13% (95% CI, 5.7–21.8). **Conclusion:** Selected uncomplicated pseudocysts can be treated effectively with a single 7-Fr DPS as it provides comparable clinical success and long-term outcomes as using larger or multiple stents.

Keywords: Drainage, endosonography, pancreatic pseudocyst, stents, therapeutic use

INTRODUCTION

Pancreatic pseudocyst (PP) is an encapsulated, well-defined, inflammatory fluid collection minimal to no necrosis.^[1] The treatment options for symptomatic or complicated PP include endoscopic, percutaneous, and surgical drainage. Endoscopic ultrasound (EUS)-guided pseudocyst drainage has gained popularity as it allows the operator to visualize both the cyst and intervening vessels, thus minimizing the risk of perforation and hemorrhage.^[2,3] Furthermore, evidence suggests that EUS-guided drainage is superior to the blinded approach, especially in cases where no extrinsic compression from pseudocyst is seen during the endoscopy, as proven by

the significantly higher technical success rate.^[4-7] The current practice for EUS-guided method is to place multiple 7- or 10-French (Fr) double pigtail stent (s) (DPS) after dilating the puncture tract.

The use of a single 7-Fr stent has been less frequently performed in practice, as it is believed that larger stents may provide better drainage and patency. Therefore, the data

Address for correspondence: Dr. Nonthalee Pausawasdi, Department of Medicine, Siriraj GI Endoscopy Center, Division of Gastroenterology, Faculty of Medicine, Siriraj Hospital, Mahidol University, Bangkok 10700, Thailand.
E-mail: nonthaleep7@gmail.com

Received: 13-10-2020 Revised: 02-12-2020 Accepted: 14-12-2020 Available Online: 14-05-2021

Access this article online

Quick Response Code:



Website:
www.jmuonline.org

DOI:
10.4103/JMU.JMU_148_20

This is an open access journal, and articles are distributed under the terms of the Creative Commons Attribution-NonCommercial-ShareAlike 4.0 License, which allows others to remix, tweak, and build upon the work non-commercially, as long as appropriate credit is given and the new creations are licensed under the identical terms.

For reprints contact: WKHLRPMedknow_reprints@wolterskluwer.com

How to cite this article: Pausawasdi N, Rugivarodom M, Rujirachun P, Charatchareonwithaya P, Chantarojanasiri T, Sirivatanauksorn Y. Effectiveness and safety of a single 7-French plastic stent for endoscopic ultrasound-guided pancreatic pseudocyst drainage and long-term follow-up outcomes. *J Med Ultrasound* 2021;29:250-7.

about the effectiveness and long-term outcomes of a single 7-Fr stent are scarce. Unlike infected pseudocyst or necrosis, a sterile uncomplicated cyst can be drained easily after stent insertion,^[8] and thus, a single 7-Fr stent may be sufficient. This study aimed to assess the effectiveness, complications, and long-term clinical outcomes of a single 7-Fr DPS as the treatment of symptomatic uncomplicated pseudocysts.

MATERIALS AND METHODS

Patient selection

A retrospective review of the EUS database between 2010 and 2018 was performed. Forty-five patients who underwent EUS-guided cystogastrostomy were identified. Thirty-one patients were excluded due to the use of multiple plastic stents, a large-sized stent (10-Fr), the lumen-apposing metallic stent (LAMS), and presence of necrosis, debris, or pus inside the cyst. Only uncomplicated pseudocyst, defined as the inflammatory cyst containing no or minimal (<10%) debris, was selected for EUS-guided drainage with a single 7-Fr DPS, and thus, 14 patients were recruited. The patient demographics, clinical presentations, cross-sectional imaging and EUS findings, complications, clinical course, and follow-up imaging were reviewed. This study was approved by the Institutional Review Board of Faculty of Medicine Siriraj Hospital, Mahidol University (COA No. Si358/2019).

Definition

An uncomplicated pseudocyst was defined as an inflammatory cyst, containing no or minimal (<10% of cyst size) debris detected by EUS. Pancreatic duct (PD) disruption was defined by the partial loss of integrity of pancreatic ductal epithelium visualized by extravasation of contrast during endoscopic retrograde pancreatography. Disconnected PD was defined as a complete transection of the main PD, resulting in an isolation of upstream tail portion of pancreas. Technical success was defined as the ability to access and successfully place a 7-Fr DPS in the pseudocyst. Clinical success was defined as complete resolution of symptoms, and more than 50% of pseudocyst regression was detected on follow-up imaging at 8 weeks after drainage.

Endoscopic procedure

EUS-guided PP drainage was performed using either a curved linear diagnostic echoendoscope with a 2.8-mm working channel (Olympus GF-UC140P-AL5) or curved linear therapeutic echoendoscope with a 3.7-mm working channel (Olympus GF-UCT140P-AL5, GF-UCT180P-AL10). The EUS assessment of cyst size, location, echogenicity, internal content, and PD connection was obtained before the cyst was punctured. Doppler was used to assess for intervening vessels. Only cysts with minimal (<10%) or no internal content were determined to be suitable for the placement of a single 7-Fr DPS. With real-time ultrasound guidance, the cyst was punctured using a 19G needle, the stylet was then removed, and cyst fluid was aspirated for analysis. Under EUS and fluoroscopy, a 0.035-inch guide-wire was inserted into the

cyst cavity making 1–2 loops inside the cyst to secure the position. The needle was then removed while leaving the wire in place. The tract was dilated using a 6-Fr cystotome followed by either an 8-mm Hurricane balloon dilator or a Soehendra dilator (6–9 Fr) depending on the operators' decision. A 7-Fr × 5-cm DPS was then placed over the guide-wire under fluoroscopic and endoscopic visualization [Figure 1].

Outcomes assessment

All of the patients in this study followed the same postprocedural care and follow-up protocol. Every patient was admitted to the hospital after the procedure for observation. Adverse events including bleeding, peritonitis, pneumoperitoneum, declined respiratory, and cardiac status developed within 24 h after the procedure were considered immediate complications. The patients were discharged after 24 h of observation on a 7-day course of either oral quinolone or cephalosporin if no complications were noted. They returned for a clinic visit at 2 weeks after discharge. A transabdominal ultrasound was performed at a 4-week interval to assess the cyst size. After clinical success was achieved, the patients were scheduled to have a clinic visit every 3 months, and an abdominal ultrasound every 6 months during the first year. After that, patients continued to have a clinical follow-up every 6 months, and an abdominal ultrasound every 12 months unless clinically indicated otherwise.

Most patients in this series underwent subsequent magnetic resonance cholangiopancreatography (MRCP) or endoscopic retrograde pancreatography (ERP) to assess PD anatomy in 4–6 weeks. If PD disconnection was noted, the transmural stent would be left in place without removal. In cases of PD leak or stricture, endoscopic treatment, including placement of a PD stent, or stricture dilation, was performed as appropriate.

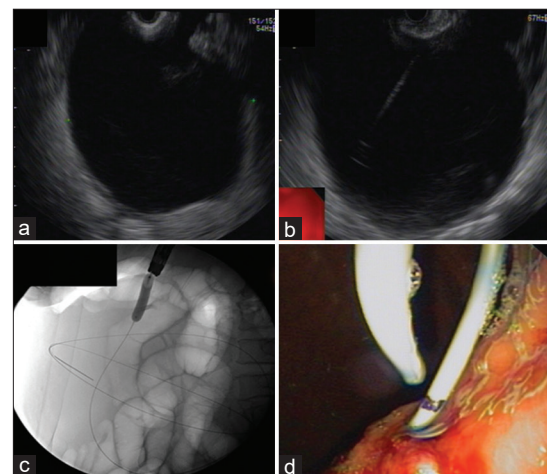


Figure 1: Pseudocyst drainage using a single 7-French double pigtail stent. (a) Endoscopic ultrasound image demonstrating a pseudocyst without internal content. (b) Endoscopic ultrasound image showing wire placement inside the cyst after puncturing with a 19G needle. (c) Fluoroscopic image of balloon dilation of the puncture tract. (d) Endoscopic ultrasound image of a single 7-French double pigtail stent placement

Once the pseudocyst resolved and the leak or stricture was adequately treated, the transmural stent was removed.

Literature review

Search strategy and study selection

Electronic searches were performed in MEDLINE and EMBASE database from the inception of the database to March 2019, by using various terms for stent drainage, EUS, and pancreatic pseudocyst. The search strategy is available in Supplementary Data 1. The eligible studies are those assessing the effectiveness or the safety of using single or multiple 7-Fr or 10-Fr plastic stent(s) for EUS-guided endoscopic transmural drainage of uncomplicated pancreatic pseudocyst. Two authors (NP and PR) independently performed all literature searches, reviews, and selections. Discrepancies were resolved through mutual consensus.

Statistical analysis

The following items from each article were collected in an Excel spreadsheet using a standardized data collection form: last name of the first author; year of publication; the study design; sex; age; the etiology of pancreatitis; number, size, and location of the pseudocyst within the pancreas; endoscopic intervention; treatment modality; type and size of the stent; duration of follow-up; and complication and response to endoscopic or surgical intervention if applicable. Data were summarized using descriptive statistics. The percentages and their 95% confidence intervals (CIs) were calculated for all the considered end points. Meta-analysis was not conducted owing to limited available published data about the treatment method of interest, which is the EUS-guided placement of a single 7-Fr DPS for pseudocyst drainage.

RESULTS

Forty-five patients were identified from the EUS database. This study recruited 14 patients (nine males, five females) presenting with symptomatic PP who underwent EUS-guided

cystogastrostomy and placement of a single 7-Fr DPS. The mean age was 48.9 ± 12.5 years. The cause of pseudocysts included gallstone in six patients (42.9%), alcohol in three patients (21.4%), blunt abdominal injury causing PD disruption in one patient (7.1%), and unknown in four patients (28.5%). The most common presentation was abdominal pain accounting for 85.7%. The mean cyst size was 10.2 ± 3.5 cm (range 5.5–16 cm). Seventy-one percent of the pseudocysts were located in the body. The majority of the pseudocysts were completely anechoic without internal echogenicity, and about 40% had echogenic content inside the cyst, occupying <10% of total cyst size [Table 1]. The technical success defined by successful guide-wire placement, tract dilation, and placement of a 7-Fr \times 5 cm DPS was 100%. All cases underwent a transgastric approach. Minor bleeding, which ceased spontaneously without requiring intervention, was noted in one case; otherwise, no immediate complications were observed. Clinical success reached 100% at follow-up [Table 2].

During the median follow-up period of 42.4 months (range 10–103 months), pseudocysts resolved without clinically significant recurrence in 92.8% of patients. Ten (70%) of 14 cases had spontaneous stent dislodgement at a mean follow-up of 18.3 months (range 0.9–53.2). Among those with stent dislodgment, none had significant recurrent pseudocysts. Two patients (14%) required additional interventions due to internal stent migration inside the cyst and stent occlusion, causing cyst infection. The patient with stent migrating inside the collapsed cyst did well without symptoms or increasing pseudocyst size at 6 months of follow-up. MRCP showed disconnected PD. EUS was repeated with an attempt to dilate the gastrostomy tract to remove the retained stent, but the tract could not be dilated adequately, and the stent could not be removed [Figure 2]. This patient subsequently underwent distal pancreatectomy given complete PD disconnection, and the retained stent was removed. The other patient developed infected

Table 1: Patient demographics and endoscopic ultrasound characteristics

Patient	Age (years)	Gender	Indications	PD status	Pancreatic pseudocyst characteristics			
					Size (cm)	Site	Echogenicity	Internal content
1	71	Male	Pain	Disconnected PD	5.5	Body	Anechoic	None
2	56	Male	Pain	Disconnected PD	15	Body	Anechoic	None
3	54	Female	Pain	Disconnected PD	9	Body	Anechoic	Minimal
4	48	Male	Pain	PD disruption	8.5	Body	Anechoic	Minimal
5	62	Male	Pain	PD disruption	6.5	Tail	Anechoic	None
6	23	Male	Pain	Disconnected PD	15	Body	Anechoic	None
7	39	Male	Pain	Disconnected PD	10	Body	Anechoic	Minimal
8	53	Male	Pain and mass	Not assessed	11.5	Body & Tail	Anechoic	Minimal
9	44	Male	Pain	Not assessed	12	Body	Anechoic	Minimal
10	58	Male	Mass	Not assessed	8	Body	Anechoic	None
11	48	Female	Pain	Not assessed	16	Body	Anechoic	Minimal
12	52	Female	Pain	PD disruption	5.5	Body	Anechoic	None
13	47	Female	Mass	Disconnected PD	12	Body and tail	Anechoic	None
14	29	Female	Pain	Disconnected PD	8	Tail	Anechoic	None

PD: Pancreatic duct

pseudocyst 8 months after the initial drainage due to stent occlusion [Figure 3] and underwent successful EUS-guided drainage of the infected pseudocyst. Despite a complete resolution of the symptoms, and regression of the infected cyst, the patient developed recurrent pseudocyst months after the transmural stents were removed. MRCP reviewed a completely disconnected PD. Given young age and unfavorable PD anatomy, cystojejunostomy was undertaken. The follow-up duration and long-term outcomes are demonstrated in Table 2.

PD status was assessed in 71% (10/14) of the patients. Of these, 40% (4/10 patients) had partial PD disruption; 7/10 (70%) had disconnected PD. The patients, diagnosed with PD leak, underwent ERP and PD stent placement, and all had complete resolution of the leak.

Literature review

The systematic search identified 369 potentially relevant articles (134 articles from EMBASE and 235 articles from MEDLINE). After the exclusion of 36 duplicated articles, 333 articles underwent title and abstract review. Two-hundred and ninety-nine articles were then excluded because they did not fulfill the eligibility criteria based on the type of article, study design, participants, and outcome of interest. Thirty-four articles were retrieved for full-length article review, and 25 articles were excluded at this stage. Finally, nine studies,^[4,5,9-15] including 222 cases who had endoscopic guided pseudocyst drainage, were eligible. The literature retrieval, review, and selection process are shown in Figure 4.

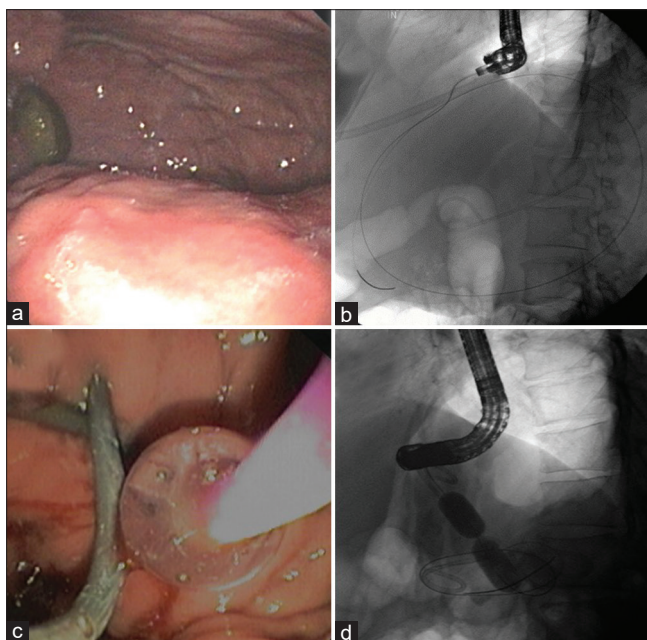


Figure 2: Internal migration of the stent. (a) Bulging of gastric wall without evidence of previously placed double pigtail stent. (b) Fluoroscopic image revealed stent migrated inside the cyst. (c) Gastrostomy tract was dilated by 15-mm balloon. (d) The stent was trapped in the collapsed cyst (appearance of the balloon's waist indicated fibrosis at gastrostomy tract)

Description of included studies

Most of the studies included small sample numbers, as described in Table 3. Three studies were prospective evaluation of EUS-guided PP drainage using mostly 10-Fr DPS, some 7-Fr DPS, and 7- or 10-Fr straight stent.^[9,11,12] One of these studies compared a one-step to two-step technique, comprising a diagnostic echoendoscope for guide-wire placement, then switched to duodenoscope for cystogastrostomy tract dilation and stent insertion.^[12] There were five comparative studies with two being randomized controlled trials.^[4,5,10,14,15] Among these, three studies compared the EUS method using either two 7-Fr DPS or single 10-Fr DPS to surgery while two compared EUS method using two 7- or 10-Fr DPS or single 10-Fr DPS to conventional transmural drainage. However, only the EUS method was included in the analysis. The largest series was a retrospective study of 61 patients, using mostly one 7- or 10-Fr straight stent.^[13] The analysis showed the pooled clinical success of 89% (95% CI, 82.0–94.2) and complication rate of 12.7% (95% CI, 5.7–21.8), which are comparable to those observed in our cohort.

DISCUSSION

EUS-guided PP drainage with single or multiple 7-Fr or 10-Fr plastic stent through a single transmural tract is the mainstay treatment for symptomatic uncomplicated pseudocyst. In contrast, infected pseudocyst or walled-off necrosis requires a larger stent or multiple transmural tracts.^[16] The association between the stent characteristics and the clinical success of endoscopic drainage of pseudocyst has been explored. A retrospective study of 122 patients showed no correlation between the size and number of the stent and the number of interventions required for treatment success in uncomplicated pseudocysts after adjusting for cyst size, location, drainage modality presence, or absence of PD stent and luminal compression. The treatment success was defined as complete resolution or decrease in the pseudocyst size to <2 cm on the follow-up CT scan performed at 8 weeks after drainage. In this study, 37% had 10-Fr stent (s) placed, and more than 60% had 7-Fr stent (s) placed. Of those who had 7-Fr stent(s), <30% (21 patients) had single stent.^[17] These results underscore

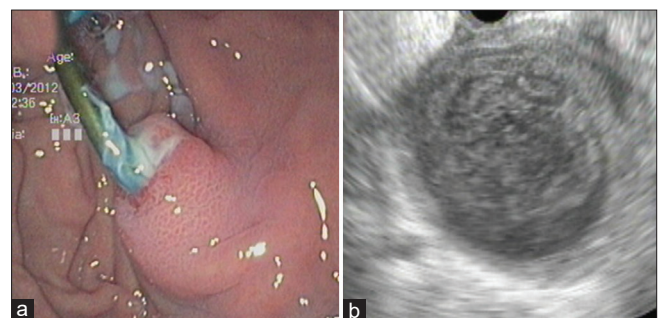
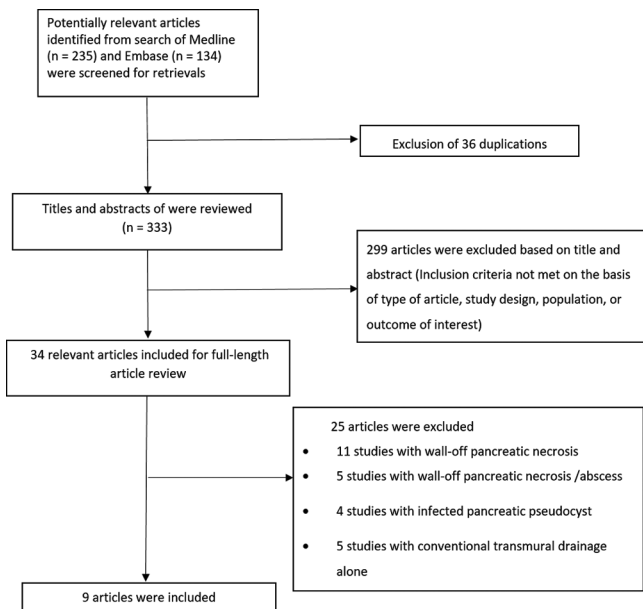


Figure 3: Infected pseudocyst. (a) Pus came through the side of pre-existing stent. (b) Linear endoscopic ultrasound revealed 5 cm x 6 cm heterogeneous hyperechoic lesion with internal content compatible with infected pseudocyst

Table 2: The effectiveness, complications and long-term clinical outcomes

Patient	Complications		Technical success	Clinical success	Follow-up duration (months)	Long-term outcomes
	Immediate	Delayed				
1	No	No	Yes	Yes	98.9	No recurrence
2	No	Stent migration inside cyst	Yes	Yes	102.8	No recurrence Distal pancreatectomy for internal stent migration and complete PD disruption
3	No	No	Yes	Yes	74.2	No recurrence
4	No	No	Yes	Yes	26.5	No recurrence
5	No	No	Yes	Yes	62.0	No recurrence
6	No	No	Yes	Yes	26.7	No recurrence
7	No	No	Yes	Yes	27.9	No recurrence
8	No	No	Yes	Yes	30.4	No recurrence
9	No	No	Yes	Yes	10.1	No recurrence
10	No	No	Yes	Yes	54.3	No recurrence
11	No	No	Yes	Yes	85.7	No recurrence
12	Minor bleeding	No	Yes	Yes	15.6	No recurrence Died of metastatic vulva cancer
13	No	No	Yes	Yes	21.9	No recurrence
14	No	Infected cyst (stent occlusion)	Yes	Yes	92.8	Recurrent infected pseudocyst Roux-en-Y cystojejunostomy

PD: Pancreatic duct

**Figure 4:** Flowchart of literature review process

the notion that cyst resolution can be easily achieved in a few weeks, regardless of the size and number of the stent. Nonetheless, the long-term clinical course has yet to be explored. However, a prospective study showed that about 22% of pseudocysts persisted at 1 month and 7% persisted at 3 months after the placement of plastic stents.^[18]

Recently, LAMS has been introduced for pancreatic fluid collection drainage. The main advantage of using metallic stents for pseudocyst drainage is to facilitate rapid cyst resolution. A recent study showed that cyst collapsed to <2 cm within 24 h in 95% of patients, and complete cyst resolution

occurred at 3 weeks in 90% of cases after metallic stent placement, and therefore, stents can be removed at 3 weeks.^[19] However, the main disadvantage of this type of stent is the cost, and significant bleeding has been noted. By far, the benefit of using LAMS in uncomplicated pseudocyst drainage over plastic stents is controversial.^[20,21]

The present study highlights the high technical and clinical success with no significant complications of EUS-guided pseudocyst drainage using a single 7-Fr stent despite a large cyst size up to 16 cm. Nevertheless, the rapid reduction of cyst fluid may easily uncoil the pigtail of a small stent, resulting in early stent migration or dislodgement. Further, the study demonstrated that two out of 14 patients had stent dislodgment or migration within 30 days, suggesting that PD defect, including leak and stenosis, should be addressed no later than 4 weeks after transmural drainage. It has been shown that PD leak or disconnection was an independent factor affecting pseudocyst resolution.^[19] In our practice, PD status was not assessed before transmural drainage because the anatomy of PD could be obscured by the large size of pseudocysts and was not always well demonstrated. Most of our patients had PD assessments between 4 and 6 weeks after transmural drainage.

After a mean follow-up of 18.3 months, stent dislodgment was noted in 70% of cases. After stent dislodgment, no recurrence of pseudocysts was noted among those without PD leaks and those receiving PD stent when a leak detected. For patients with PD disruption (7/14 cases), most of them did not have recurrent pseudocyst after stent dislodged; however, two patients required additional endoscopic interventions. One patient had stent migrated and trapped in the collapsed cyst that later required distal pancreatectomy for definitive treatment of PD disruption and stent removal. The other patient presented

Table 3: Characteristics of studies included in the systematic review

Author/year	Design	n	Etiology	Mean cyst size (cm)	Plastic stent		Endoscopic treatment results			Follow-up results	
					Size	No	Technical success	Clinical success	Complication	Duration	Long-term outcomes
Ahlawat <i>et al.</i> , 2006 ^[9]	PS	11	55% alcohol 18% biliary pancreatitis 9% acute pancreatitis 9% chronic pancreatitis	7.7	10-Fr DPS	81% one 19% two	100%	73%	27%	4 months	3 stent migrations: 1 surgical cystogastrostomy the following day 2 recurrences from stent migration (1 surgical cystogastrostomy, 1 repeat EUS-guided drainage)
Kahaleh <i>et al.</i> , 2006 ^[10]	PS	46 EUS versus 53 CTD	44% alcohol 34% gallstone 10% hyper-TG 6% idiopathic 6% PEP	EUS: 8.6	10-Fr DPS	1 or 2	100%	EUS: 84% CTD: 91%	EUS: 20% CTD: 20%	6 months	Stent migration EUS: 2%, CTD: 4% Infection EUS: 9%, CTD: 8%
Jansen <i>et al.</i> , 2007 ^[11]	PS	8	NA	14	7, 10-Fr DPS	3	100%	100%	None	6 weeks	100% complete resolution
Varadarajulu <i>et al.</i> , 2008 ^[5]	RCT	14 EUS versus 15 CTD	34% alcohol 31% idiopathic 14% gallstone 10% postsurgery	EUS: 7	7-Fr DPS (EUS) 10-Fr DPS (CTD)	2	EUS: 100% EGD: 33.3%	EUS: 100% CTD: 87%	EUS: None CTD: 13.3%	6 months	Two major procedure-related bleeding in CTD No recurrence reported
Varadarajulu <i>et al.</i> , 2008 ^[4]	RT	20 EUS versus 10 Sx	60% idiopathic 20% gallstone 20% alcohol	EUS: 9.8	Two 7-Fr or single 10-Fr DPS	1 or 2	EUS: 100% Sx: 100%	EUS: 95% Sx: 100%	None	2 years	Re-intervention EUS: None Sx: 10%
Mangiavillano <i>et al.</i> , 2012 ^[12]	PS	21 Group A: 13 Group B: 8	52% chronic pancreatitis 24% acute pancreatitis 24% trauma	Group A: 9 Group B: 10	A: 10-Fr DPS B: 10-Fr DPS or 10/7-Fr SS	1	A: 92% B: 75%	A: 100% B: 83%	A: 15% B: 25%	3 months	Recurrence A: 15% B: 12.5%
Ng <i>et al.</i> , 2013 ^[13]	RT	61	58% alcohol 16% gallstone 15% idiopathic 11% trauma	7.5	7,10-Fr SS	77% one 23% two	93%	75%	25%	45 weeks	Recurrence: 10%

Contd...

Table 3: Contd...

Author/year	Design	n	Etiology	Mean cyst size (cm)	Plastic stent		Endoscopic treatment results			Follow-up results	
					Size	No	Technical success	Clinical success	Complication	Duration	Long-term outcomes
Varadarajulu <i>et al.</i> , 2013 ^[14]	RCT	20 EUS versus 20 Sx	37% alcohol 40% gallstone 23% idiopathic	EUS: 10.5	N/A	2	N/A	EUS: 95% Sx: 100%	EUS: None Sx: 10%	N/A	Recurrence EUS: None Sx: 5%
Saul <i>et al.</i> , 2016 ^[15]	RT	21 EUS versus 43 Sx	40% gallstone 10% hyper-TG 5% alcohol 45% unspecified	EUS: 6.7	7-Fr DPS	2	N/A	EUS: 90.5% Sx: 90.7%	EUS: 23.8% Sx: 25.6%	270 days (EUS) 580 days (Sx)	Recurrence EUS: 9.5% Sx: 4.6%
Pausawasdi <i>et al.</i> , (Present study)	RT	14	43% gallstone 21% alcohol 7% abdominal injury 29% unspecified	10.2	7-Fr DPS	1	100%	100%	14%	Median of 42.2 months (range 10-103)	1/14 (7%) recurrence 1/14 (7%) internal migration

RT: Retrospective, RCT: Randomized control trial, PS: Prospective, EUS: Endoscopic ultrasound, CTD: Conventional transmural drainage, PEP: Post-ERCP pancreatitis, hyper-TG: Hypertriglyceridemia, DPS: double pig tail plastic stent, SS: Straight plastic stent, Sx: Surgery, NA: Not available, Fr: French, ERCP: Endoscopic retrograde cholangiopancreatography

with infected pseudocyst due to stent occlusion requiring endoscopic drainage, which occurred within 8 months after stent placement. This study used both an 8-mm Hurricane balloon and a 6–9-Fr Soehendra dilator for cystogastrostomy tract dilation. The discrepancy between the cystogastrostomy tract size and the stent size might have contributed to the stent migration; however, we could not demonstrate the correlation between these two factors. The factor that has been shown to increase the risk of stent migration is a straight plastic stent.^[22] None reported delayed stent-related complications for those patients who retained indwelling DPS throughout the study period, suggesting that a transmural plastic stent can be left in place safely long term, and should be especially considered for those with complete PD disconnection.

To further explore the efficacy and long-term clinical outcomes of EUS-guided PP drainage with a single 7-Fr DPS, a systematic literature review was performed. Despite strict inclusion criteria, the review recruited several different types and sizes of plastic stents. Thus, the analysis in the format of the meta-analysis was not conducted. The most common etiology for pseudocysts from the included studies was alcohol, whereas gallstone was the most common cause in the present study. However, the cyst characteristics, defined as uncomplicated cyst without necrosis or infection, and the average of cyst size (9 cm) were similar to our cohort. The stent migration mostly occurred early within weeks to a few months, but one study reported the internal migration of a 10-Fr stent within

1 day. Our study reported two patients with stent migration in <30 days, but most cases had stent dislodgment at 18 months. It may be that early stent migration was related to rapid cyst regression and larger cystogastrostomy tract from placing multiple stents. The reported recurrence rate of pseudocysts from the literature review was 10%–15%, compared to 7% in our study, but no data were available on long-term outcomes beyond 1 year.

The pooled analysis revealed comparable rate of clinical success and complications related to stent migration to our study cohort. This finding supports the notion that the size and numbers of stent do not matter to the treatment success in uncomplicated pseudocysts. The technical success ranges between 92% and 100%, but the success rate dropped to 75% with the two-step technique owing to losing guide-wire access during the scope exchange from a diagnostic echoendoscope to a duodenoscope. This challenge can be overcome by placing a single 7-Fr stent through the diagnostic echoendoscope (2.8-mm working channel) and avoid scope exchange when a therapeutic echoendoscope is not available.

This study's strength is the long-term follow-up period with a median of 42.4 months (range, 10–103) compared to a follow-up period ranging from 1 to 24 months in the available literature. All of the patients followed the same protocol with a scheduled follow-up visit and imaging; therefore, there were no missing data despite being a retrospective study. However,

this study shares the same limitation as to other studies, which is a small number of cases.

CONCLUSION

Taken together, a single 7-Fr DPS for pseudocyst drainage is effective, safe, and technically simple. It provides similar technical and clinical success, and long-term clinical outcomes as multiple or larger stents; thus, selected pseudocysts can be treated successfully with a single 7-Fr DPS with respectable long-term results.

Financial support and sponsorship

Nil.

Conflicts of interest

There are no conflicts of interest.

REFERENCES

1. Banks PA, Bollen TL, Dervenis C, Gooszen HG, Johnson CD, Sarr MG, *et al.* Classification of acute pancreatitis-2012: Revision of the Atlanta Classification and Definitions by International Consensus. *Gut* 2013;62:102-11.
2. Giovannini M, Bernardini D, Seitz JF. Cystogastrostomy entirely performed under endosonography guidance for pancreatic pseudocyst: Results in six patients. *Gastrointest Endosc* 1998;48:200-3.
3. Vilmann P, Hancke S, Pless T, Schell-Hincke JD, Henriksen FW. One-step endosonography-guided drainage of a pancreatic pseudocyst: A new technique of stent delivery through the echo endoscope. *Endoscopy* 1998;30:730-3.
4. Varadarajulu S, Christein JD, Tamhane A, Drelichman ER, Wilcox CM. Prospective randomized trial comparing EUS and EGD for transmural drainage of pancreatic pseudocysts (with videos). *Gastrointest Endosc* 2008;68:1102-11.
5. Varadarajulu S, Lopes TL, Wilcox CM, Drelichman ER, Kilgore ML, Christein JD, *et al.* EUS versus surgical cyst-gastrostomy for management of pancreatic pseudocysts. *Gastrointest Endosc* 2008;68:649-55.
6. Park DH, Lee SS, Moon SH, Choi SY, Jung SW, Seo DW, *et al.* Endoscopic ultrasound-guided versus conventional transmural drainage for pancreatic pseudocysts: A prospective randomized trial. *Endoscopy* 2009;41:842-8.
7. Panamonta N, Ngamruengphong S, Kijirichareanchai K, Nugent K, Rakvit A. Endoscopic ultrasound-guided versus conventional transmural techniques have comparable treatment outcomes in draining pancreatic pseudocysts. *Eur J Gastroenterol Hepatol* 2012;24:1355-62.
8. Sadik R, Kalaitzakis E, Thune A, Hansen J, Jönson C. EUS-guided drainage is more successful in pancreatic pseudocysts compared with abscesses. *World J Gastroenterol* 2011;17:499-505.
9. Ahlawat SK, Charabaty-Pishvaian A, Jackson PG, Haddad NG. Single-step EUS-guided pancreatic pseudocyst drainage using a large channel linear array echoendoscope and cystotome: Results in 11 patients. *JOP* 2006;7:616-24.
10. Kahaleh M, Shami VM, Conaway MR, Tokar J, Rockoff T, De La Rue SA, *et al.* Endoscopic ultrasound drainage of pancreatic pseudocyst: A prospective comparison with conventional endoscopic drainage. *Endoscopy* 2006;38:355-9.
11. Jansen JM, Hanrath A, Rauws EA, Bruno MJ, Fockens P. Intracystic wire exchange facilitating insertion of multiple stents during endoscopic drainage of pancreatic pseudocysts. *Gastrointest Endosc* 2007;66:157-61.
12. Mangiavillano B, Arcidiacono PG, Masci E, Mariani A, Petrone MC, Carrara S, *et al.* Single-step versus two-step endo-ultrasonography-guided drainage of pancreatic pseudocyst. *J Dig Dis* 2012;13:47-53.
13. Ng PY, Rasmussen DN, Vilmann P, Hassan H, Gheorman V, Burtea D, *et al.* Endoscopic ultrasound-guided drainage of pancreatic pseudocysts: Medium-term assessment of outcomes and complications. *Endosc Ultrasound* 2013;2:199-203.
14. Varadarajulu S, Bang JY, Sutton BS, Trevino JM, Christein JD, Wilcox CM, *et al.* Equal efficacy of endoscopic and surgical cystogastrostomy for pancreatic pseudocyst drainage in a randomized trial. *Gastroenterology* 2013;145:583-900.
15. Saul A, Ramirez Luna MA, Chan C, Uscanga L, Valdovinos Andraca F, Hernandez Calleros J, *et al.* EUS-guided drainage of pancreatic pseudocysts offers similar success and complications compared to surgical treatment but with a lower cost. *Surg Endosc* 2016;30:1459-65.
16. Holt BA, Varadarajulu S. The endoscopic management of pancreatic pseudocysts (with videos). *Gastrointest Endosc* 2015;81:804-12.
17. Bang JY, Wilcox CM, Trevino JM, Ramesh J, Hasan M, Hawes RH, *et al.* Relationship between stent characteristics and treatment outcomes in endoscopic transmural drainage of uncomplicated pancreatic pseudocysts. *Surg Endosc* 2014;28:2877-83.
18. Arvanitakis M, Delhay M, Bali MA, Matos C, De Maertelaer V, Le Moine O, *et al.* Pancreatic-fluid collections: A randomized controlled trial regarding stent removal after endoscopic transmural drainage. *Gastrointest Endosc* 2007;65:609-19.
19. Dhir V, Teoh AY, Bapat M, Bhandari S, Joshi N, Maydeo A, *et al.* EUS-guided pseudocyst drainage: Prospective evaluation of early removal of fully covered self-expandable metal stents with pancreatic ductal stenting in selected patients. *Gastrointest Endosc* 2015;82:650-7.
20. Isayama H, Nakai Y, Rerknimitr R, Khor C, Lau J, Wang HP, *et al.* Asian consensus statements on endoscopic management of walled-off necrosis. Part 2: Endoscopic management. *J Gastroenterol Hepatol* 2016;31:1555-65.
21. Lang GD, Fritz C, Bhat T, Das KK, Murad FM, Early DS, *et al.* EUS-guided drainage of peripancreatic fluid collections with lumen-apposing metal stents and plastic double-pigtail stents: Comparison of efficacy and adverse event rates. *Gastrointest Endosc* 2018;87:150-7.
22. Cahen D, Rauws E, Fockens P, Weverling G, Huibregtse K, Bruno M, *et al.* Endoscopic drainage of pancreatic pseudocysts: Long-term outcome and procedural factors associated with safe and successful treatment. *Endoscopy* 2005;37:977-83.